

OVERVIEW of the URINARY SYSTEM

Excretion involves the elimination of the waste products of cellular metabolism. It also encompasses the removal of surplus materials from the body tissues, and it includes regulation of the water and salt content of the body. Regulatory functions such as these are accomplished by the kidneys and their accessory structures in the urinary system. In this plate, we present an overview of the urinary system in anterior, posterior, and inferior views. We indicate the major organs of this system and their location and structure and prepare for a detailed study in the plates ahead.

The plate shows the organs of the urinary system in three views. In anterior and posterior views, the organs are shown relative to each other and to other nearby structures. The major thrust of the third diagram is to indicate the position of the kidneys relative to the peritoneal cavity. You may begin by coloring the main title Overview of the Urinary System. Then, as you read the text below, locate the titles and the structures on the diagrams. The anterior and posterior views should be colored before proceeding to the inferior view.

The main organs of excretion in the body are the **kidneys (A₁ and A₂)**. The same pale color is recommended for both kidneys; the numbers are used to indicate left and right kidneys respectively.

The kidneys are bean-shaped organs roughly about the size of the fist. They are located on each side of the vertebral column and usually extend from the twelfth thoracic vertebra to the third lumbar vertebra. As the posterior view shows, the twelfth rib partially protects them. The upper portion of each kidney is in contact with a part of the diaphragm, and the **left kidney (A₁)** touches the spleen. The **right kidney (A₂)** is near the liver and is slightly lower.

We now turn to the blood supply of the kidney and discuss it briefly. The passageways for blood have been mentioned previously in the discussion of the circulatory system, and we review them here. As you encounter the structures in the reading below, color their titles, then color them in the anterior and posterior views.

Leading from the kidneys are the two tubes, the **ureters (B)**. These tubes carry urine away from the kidney. The ureters lead to the main storage organ, the **urinary bladder (C)**. This hollow muscular sac is located in the midline at the floor of the pelvic cavity. The bladder is discussed in more detail in an upcoming plate.

The tube leading from the bladder to the exterior is the **urethra (D)**. This tube of smooth muscle is about one and a half inches long in the female and about eight inches long in the male as it passes through the penis.

We now turn to the blood supply of the kidney and discuss it briefly. The passageways for blood have been mentioned previously in the discussion of the circulatory system, and we review them here. As you encounter the structures in the reading below, color their titles, then color them in the anterior and posterior views.

The main circulatory vessel transporting blood to the kidney is the **renal artery (E)**, clearly seen in the posterior view. The **renal vein (F)** lies behind the renal artery in the posterior view and, therefore, is difficult to see. A light color is recommended. The renal vein transports blood away from the kidney after it has been cleansed. The renal artery is supplied with blood by the **abdominal aorta (G)**, while the renal vein empties its blood into the **inferior vena cava (H)**. Lying on top of the kidneys are the **suprarenal glands (J)**, discussed with the endocrine system.

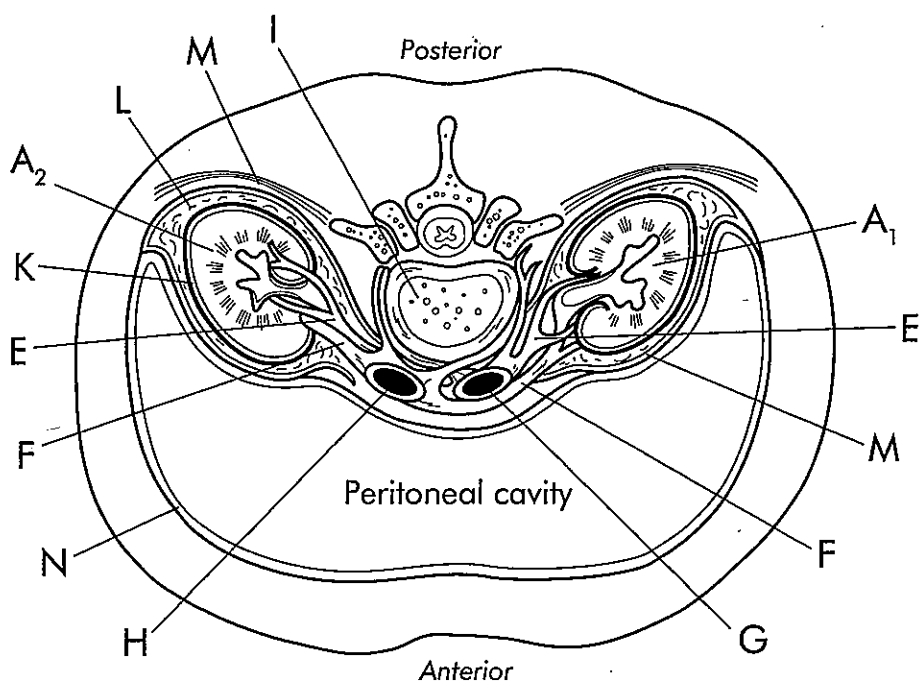
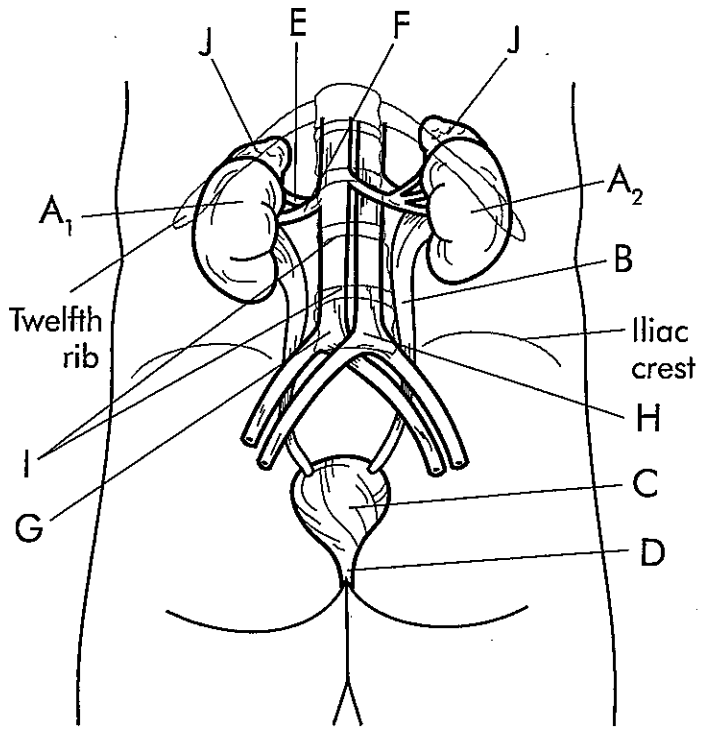
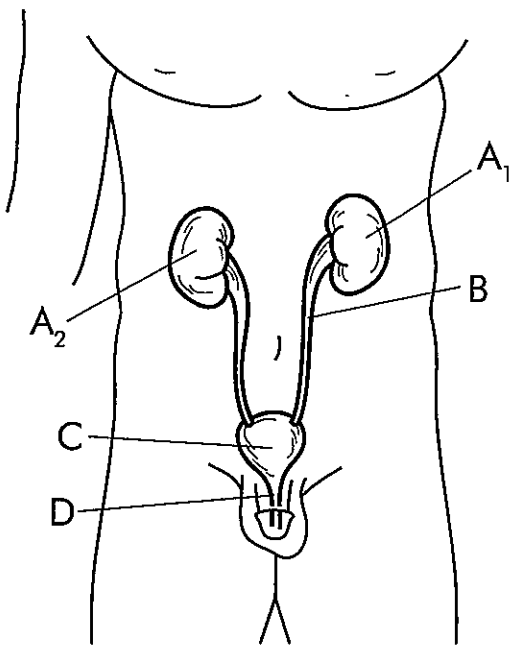
We close the plate with a transverse section through the body and a view from the inferior aspect. We are looking down from above at the level of the stomach, transverse colon, pancreas, and other organs of the abdominal cavity. These organs have been removed to reveal an empty peritoneal cavity. A gray color may be used for this cavity. Our objective is to view the organs of the urinary system in position and to indicate some of their coverings.

The view in the plate shows the organs of several systems. For example, we see an outline of the **lumbar vertebra (I)**, and the spinal cord is visible. Sections are also shown through the **kidneys (A₁ and A₂)**. Note the **renal artery (E)** arising on the right and left sides from the **abdominal aorta (G)**. Also note the **renal veins (F)** leading on both sides to the **inferior vena cava (H)**.

The kidney is surrounded by three layers of supportive tissue. Immediately adhering to the kidney surface is the **renal capsule (K)**. A dark color may be used to highlight this layer. The capsule is composed of fibrous tissue providing an impenetrable barrier to infection of the kidney surface. Outside the renal capsule is a middle covering layer of fat. It is called the **adipose capsule (L)**. A pale color is recommended. The fat tissue of the capsule helps cushion the kidney against blows. Outside the adipose capsule is the **renal fascia (M)**. A dark color is also recommended to outline this layer. The fascia is composed of dense fibrous connective tissue. It helps protect the kidney and adrenal glands while anchoring these organs to the nearby tissues.

Like many organs of the digestive system, the kidneys lie outside the peritoneal cavity. This position is called retroperitoneal. As the diagram shows, the peritoneal cavity is bordered by the **peritoneum (N)**. The continuous nature of this membrane can be seen, and you may note that the kidneys are not within the membrane.

OVERVIEW OF THE URINARY SYSTEM



- | | | |
|--------------------|----------------|---|
| Left kidney | A ₁ | ○ |
| Right kidney | A ₂ | ○ |
| Ureter | B | ○ |
| Urinary bladder | C | ○ |
| Urethra | D | ○ |
| Renal artery | E | ○ |
| Renal vein | F | ○ |
| Abdominal aorta | G | ○ |
| Inferior vena cava | H | ○ |
| Lumbar vertebra | I | ○ |
| Suprarenal glands | J | ○ |
| Renal capsule | K | ○ |
| Adipose capsule | L | ○ |
| Renal fascia | M | ○ |
| Peritoneum | N | ○ |

the KIDNEY

The two major organs of excretion are the kidneys. Lying between the dorsal body wall and the parietal peritoneum, the kidneys are retroperitoneal. An average adult kidney weighs approximately five ounces and is about the size of the heart.

In this plate, we study the regions and blood supply of the kidney. The plate consists of the two sections. In the first section, a mix of dark and light colors may be used according to the area designated, whereas in the second section, light colors are best because the blood vessels tend to be small.

In this plate, we present frontal sections of the right kidney. The first diagram is used to designate the important areas and regions of the kidney, while the second diagram indicates its blood supply. Beginning with the first diagram, read the following section, and as you encounter the structures, color their titles, then locate them and color them in the plate. Darker greens, reds, and blues are recommended, except where indicated.

At its outer surface, each kidney is surrounded by a fibrous membrane known as the **capsule (A)**. The capsule helps maintain the shape of the kidney.

Within the section of the kidney, there are two distinct regions. The first is the **renal cortex (B)**, the more superficial area extending around the rim of the kidney. A pale tan or gray is recommended to color the entire cortex. Deep to the cortex is another major portion of the kidney known as the **renal medulla (C)**. A bracket outlines this area, and a light color is recommended. Similar pale colors may be utilized later.

Within the renal medulla, the kidney has a number of cone-shaped tissue masses called **renal pyramids (D)**. Appearing as brushlike structures in the diagram, there are approximately eight to eighteen pyramids in each kidney. The **base (D₁)** of the pyramid faces the renal cortex, while the apex or **renal papilla (D₂)** points toward the center of the kidney. The pyramids are formed of bundles of tubules that collect urine. Separating the pyramids are masses of cortical tissue extending inward from the cortex and known as **renal columns (L)**. A renal pyramid and the cortical tissue outside it constitute a lobe of the kidney.

We now focus at the area at the center of the kidney and indicate the tubes entering and leaving this area. Continue your reading as before and color the titles of the structures as you encounter them. Then locate them in the section of the kidney and color them in.

As the diagram shows, the lateral surface of the kidney is convex. Its medial surface is concave and has a large cleft known as the **hilus (E)**. The hilus leads to a space within the kidney known as the **renal sinus (F)**. Within the sinus are blood vessels, lymphatic vessels, and nerves. The **renal artery (M)** and the **renal vein (N)** occupy a portion of the sinus.

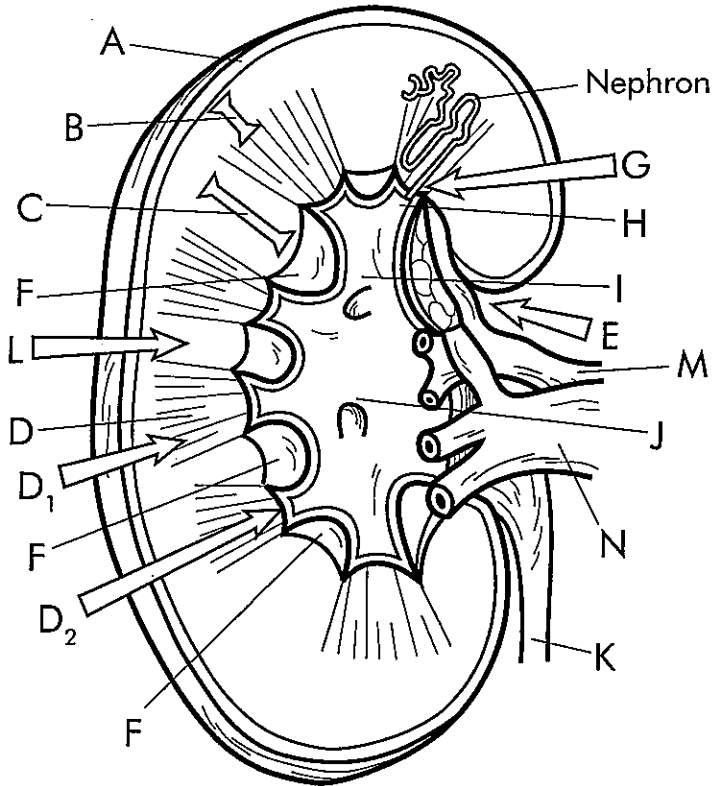
Within the renal sinus is a flat, funnel-like tube called the **renal pelvis (J)**. The pelvis is continuous with the **ureter (K)**. Urine is produced in tubules occupying the cortex and medulla in a complex arrangement called the nephron. One such nephron is pointed out in the diagram, and nephrons are discussed in more detail in the next plate. The tube carrying urine from the nephron is the **papillary duct (G)**, indicated by an arrow. The papillary duct leads to a cuplike structure called the **minor calyx (H)**, where urine collects. The minor calyces lead to two or three **major calyces (I)**. The major calyces empty their contents of urine into the renal pelvis, which leads to the ureter.

We now examine the vascular system operating within the kidney. For this purpose, we focus on the second diagram of the plate and the blood flowchart. This circulation through the kidney provides a pathway for the entry and exit of blood. Within the kidney tissues, the blood is cleansed in the nephrons, as explained in the next plate.

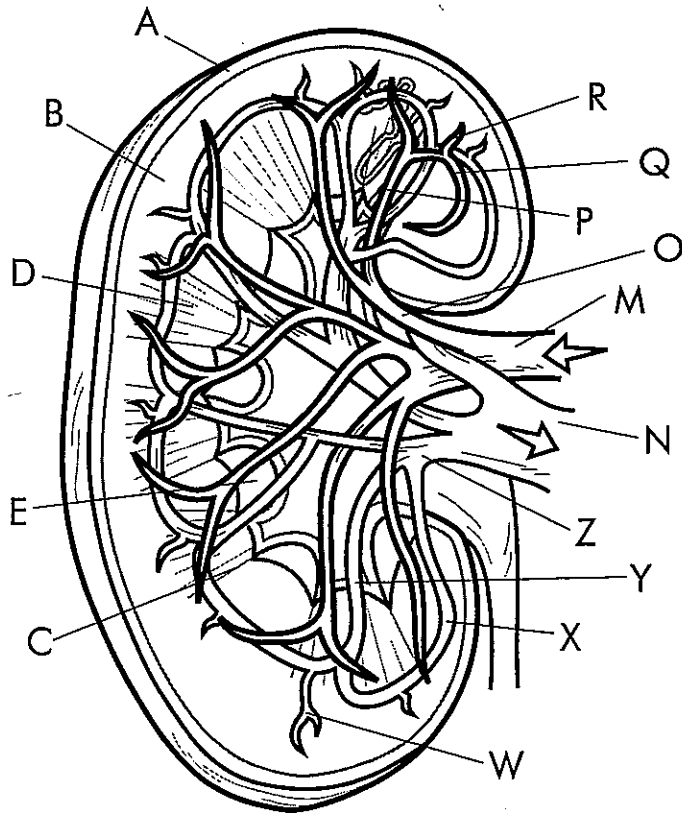
As previously noted, blood enters the kidney through the **renal artery (M)** at the hilus. Just beyond the hilus, the renal artery separates to form five **segmental arteries (O)**. A pale shade of red is recommended for this artery, and variations of the red may be used for successive arteries.

Leaving the segmental artery, blood flows into an **interlobar artery (P)**. Note how the blood flows out toward the cortex through this artery. You should search for other interlobar arteries paralleling this one. Near the junction of medulla and cortex tissues, the interlobar artery divides and gives rise to several **arcuate arteries (Q)**. Note how these arteries form arches at the bases of the renal pyramids.

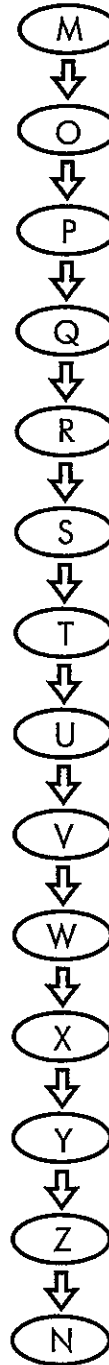
From the arcuate arteries arise the **interlobular arteries (R)**. The cortex tissue is supplied with blood by these arteries. They eventually lead to **afferent arteries (S)**, which are indicated only in the flowchart. The afferent arteries enter a **glomerulus (T)**, also indicated only in the flowchart. The glomerulus is discussed in detail in the next plate. Blood leaves the glomerulus in the **efferent arteriole (U)** and enters a **peritubular capillary (V)**. The **interlobular vein (W)** arises from the peritubular capillary and leads blood to the **arcuate vein (X)**. Arcuate veins lead blood to the **interlobar veins (Y)**, which can be seen extending down toward the sinus. The interlobar veins unite to form **segmental veins (Z)**, which come together to form the **renal vein (N)**. This vein leads blood out of the kidney and completes the circuit.



Frontal section of right kidney



Blood Flowchart



- | | | |
|-----------------------|----------------|-----------------------|
| Capsule | A | <input type="radio"/> |
| Renal cortex | B | <input type="radio"/> |
| Renal medulla | C | <input type="radio"/> |
| Renal pyramids | D | <input type="radio"/> |
| Base | D ₁ | <input type="radio"/> |
| Apex (renal papilla) | D ₂ | <input type="radio"/> |
| Hilus | E | <input type="radio"/> |
| Renal sinus | F | <input type="radio"/> |
| Papillary duct | G | <input type="radio"/> |
| Minor calyx | H | <input type="radio"/> |
| Major calyces | I | <input type="radio"/> |
| Renal pelvis | J | <input type="radio"/> |
| Ureter | K | <input type="radio"/> |
| Renal columns | L | <input type="radio"/> |
| Renal artery | M | <input type="radio"/> |
| Renal vein | N | <input type="radio"/> |
| Segmental arteries | O | <input type="radio"/> |
| Interlobar artery | P | <input type="radio"/> |
| Arcuate arteries | Q | <input type="radio"/> |
| Interlobular arteries | R | <input type="radio"/> |
| Afferent arteries | S | <input type="radio"/> |
| Glomerulus | T | <input type="radio"/> |
| Efferent arteriole | U | <input type="radio"/> |
| Peritubular capillary | V | <input type="radio"/> |
| Interlobular vein | W | <input type="radio"/> |
| Arcuate vein | X | <input type="radio"/> |
| Interlobar veins | Y | <input type="radio"/> |
| Segmental veins | Z | <input type="radio"/> |

the NEPHRON

The independent unit within the kidney that produces urine is the nephron. There are approximately one million nephrons in each kidney. Nephrons perform the functions of filtration, reabsorption, and secretion. A basic understanding of kidney function can be obtained by understanding the activities at the nephron.

This plate reviews the structures associated with the nephron. We briefly discuss the formation of urine and see how the kidney performs its excretory functions.

Looking over the plate, you will note that it is composed of three diagrams: a diagram of the kidney progressing to a detailed presentation of a microscopic unit of the kidney. Bold colors may be used throughout this diagram, and contrasting colors are recommended as we proceed. Color the main title The Nephron, then read below and color the titles and structures as you discuss them in the reading.

The million or so nephrons of each kidney contain the same basic set of tubular and vascular components. In the first diagram, we see the **kidney (A)**, as seen in previous plates. A dark color may be used. One area of the kidney is shown in detail. This area contains a **nephron (B)**. A pale shading is recommended to highlight it. The **renal artery (C)** delivers blood to the kidney, while the **renal vein (D)** removes it from the kidney, and the **ureter (E)** is responsible for carrying urine away.

We now focus on an exploded view of the kidney, where we see eight nephrons. We briefly review this region before going on to the detailed view of the nephron. As you read about the structures, color them in as recommended.

The second diagram of the plate shows the two main areas of the kidney. The first area is the **cortex (F)**, indicated by a bracket. The bracket should be colored in a bold color, and the general area can be colored in a pale hue. The second area is the **medulla (G)**.

Within the cortex and medulla we present the outlines of eight nephrons. Each of the eight nephrons has a **renal corpuscle (H)**. The renal corpuscles of **cortical nephrons (H₁)** have tubular structures extending to the base of the renal pyramid. By comparison, the renal corpuscles of **juxtamedullary nephrons (H₂)** have tubules extending deep into the renal pyramid, as explained in the previous plate. For each of these nephrons, we recommend that you color in the cuplike renal corpuscle then color in the tubule leading from the corpuscle as it extends toward a collecting duct. The collecting duct receives urine from many nephrons. The tubules associated with the other seven nephrons are not shown in this diagram.

Now we come to the nephron itself. Recall that there are vascular and tubular components. We recommend your using variations of one color for all components of the vascular component, and variations of a contrasting color for all components of the tubular component. Portions of the components blend with one another so that the variations of color should be continuous. Continue reading as you study the nephron, and color the structures as you come upon them.

As noted previously, blood passes through a series of arteries described in the previous plate, including the segmental, interlobar, arcuate, and finally the **interlobular artery (J)**. A branch of this artery is the **afferent arteriole (K)**. Blood flows through this vessel into a tuft of capillaries called the **glomerulus (L)**. Filtration takes place here, then the blood leaves and enters a vessel called the **efferent arteriole (M)**. The efferent arteriole branches into a network of capillaries, the **peritubular capillary network (N)**. We recommend using a single color for these vascular tubes, with variations to show where one passageway ends and another begins.

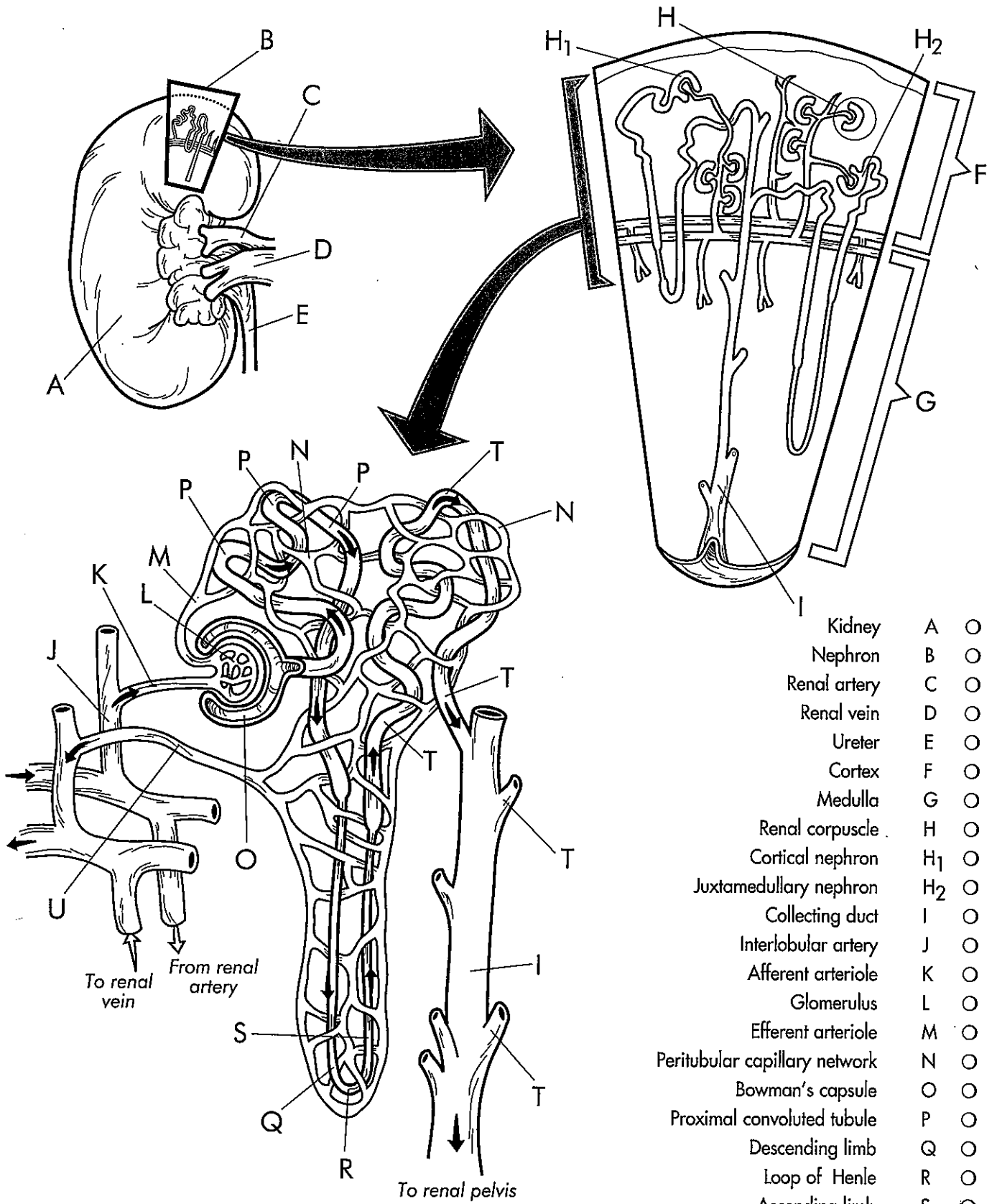
As blood passes through the glomerulus, it is forced into the wall of the cuplike structure called **Bowman's capsule (O)**. (The combination of glomerulus and Bowman's capsule is the renal corpuscle.) Blood fluid is forced out of the glomerulus into the walls of the Bowman's capsule, then into the remainder of the tubular component. First encountered is the **proximal convoluted tubule (P)**. At this point, useful substances such as water, sodium ions, glucose, and amino acids are reabsorbed back to the blood in the peritubular network.

At this point, note that the proximal tubule descends toward the renal medulla, seen earlier. In the diagram, the descending tubule is called the **descending limb (Q)**. The tubule turns abruptly at the **loop of Henle (R)** and ascends as the **ascending limb (S)**. A variation of the same color used for the proximal tubule should be used for these portions. The peritubular capillaries surround the tubules in this area, and precise amounts of water and salts are reabsorbed back into the blood.

As the tubule ascends, it forms the **distal convoluted tubule (T)**. Again, it winds with capillaries of the **peritubular capillary network (N)**, and selective reabsorption takes place. The capillary network eventually moves back in the direction of the renal corpuscle and forms the **interlobular vein (U)**. This vein leads to the arcuate vein, interlobar vein, and finally to the renal vein to remove the cleansed blood from the kidney.

Following the tubule once again, note that the **distal convoluted tubule (T)** comes to the **collecting duct (I)**. The fluid present in the collecting tubules is urine. The collecting duct receives urine from several tubules and sends it to the renal pelvis for discharge.

THE NEPHRON



- Kidney A ○
- Nephron B ○
- Renal artery C ○
- Renal vein D ○
- Ureter E ○
- Cortex F ○
- Medulla G ○
- Renal corpuscle H ○
- Cortical nephron H₁ ○
- Juxtamedullary nephron H₂ ○
- Collecting duct I ○
- Interlobular artery J ○
- Afferent arteriole K ○
- Glomerulus L ○
- Efferent arteriole M ○
- Peritubular capillary network N ○
- Bowman's capsule O ○
- Proximal convoluted tubule P ○
- Descending limb Q ○
- Loop of Henle R ○
- Ascending limb S ○
- Distal convoluted tubule T ○
- Interlobular vein U ○